

## Oral Lichen Planus - Review on Etiopathogenesis and Management

Belgasesm KA<sup>1</sup> and Abdalmawla Alhussin Ali Ali<sup>2</sup>

<sup>1</sup>Department of Oral Pathology, Faculty of Dentistry, Sirte University, Libya

<sup>2</sup>Department of Orthodontics, Faculty of Dentistry, Sirte University, Libya

**\*Corresponding Author:** Abdalmawla Alhussin Ali Ali, DDS, MDentSci (Ortho), is Lecturer in Orthodontic, Faculty of Dentistry, Sirte University, Libya, Tel: 00218922665344, E-mail: [abdalmawla.ali@su.edu.ly](mailto:abdalmawla.ali@su.edu.ly)

**Citation:** Belgasesm KA, Abdalmawla Alhussin Ali Ali (2021) Oral Lichen Planus - Review on Etiopathogenesis and Management. *Technolock J Dent* 1:1-9

**Copyright:** © 2021 Abdalmawla Alhussin Ali. This is an open-access article distributed under the terms of Creative Commons Attribution License, which permits unrestricted use, distribution, and reproduction in any medium, provided the original author and source are credited.

### ABSTRACT

Oral Lichen planus (OLP) is a common chronic mucocutaneous disorder of uncertain etiopathogenesis, but it is thought to be the result of an autoimmune process. With several factors including stress, genetics, systemic diseases, viruses, dental restorative materials and drugs have been implicated as causative agents. The disease seems to be mediated by an antigen specific mechanism, activating cytotoxic T cells, and non-specific mechanisms like mast cell degranulation and matrix metalloproteinase activation. Oral lichen planus is a complex and poorly understood clinical condition with periods of remissions and exacerbations. Malignant transformation of OLP remains a controversy and variably reported between 0% and 5%. Management of the OLP is diversified with few lesions requiring treatment for years and few others are mild, requiring no treatment. A proper understanding of the pathogenesis, clinical presentation, diagnosis of the disease becomes important for providing the right treatment.

**Keywords:** Mucocutaneous Disease; Oral Lichen Planus; Malignant Transformation; Corticosteroids

## Introduction

Lichen planus is a chronic inflammatory disease that affects the skin and the mucus membrane. Oral lichen planus (OLP), the mucosal counterpart of cutaneous lichen planus, the buccal mucosa, tongue and the gingiva are commonly involved although other sites may be rarely affected [1]. Occurring most commonly in the middle aged women [2]. However, few cases have been reported in children as young as 6 months [3] OLP is although to be relatively common, affecting approximately 1-2% of population. There is no racial predilection, and the disease appears to be pan racial. OLP should be considered as a potentially malignant disorder because there is a relationship between oral cancer and OLP, although the degree of risk involved is variable [4,5].

## Etiology

The etiology and pathogenesis of OLP has been the focus of much research, and several antigen-specific and nonspecific inflammatory mechanisms have been put forward to explain the pathogenesis. The etiology of OLP appears to be multifactorial and complicated. Earlier studies have implicated stress, anxiety, depression as the causes for OLP [6,7]. However, whether stress is the cause or the consequence was left undetermined. Familial cases of OLP have been reported and role of genetic predisposition was considered.

Certain systemic diseases like diabetes mellitus, hypertension, ulcerative colitis, myasthenia gravis, lupus erythematosus, etc were considered to be associated with OLP [8]. Lodi G et al. [9] reported that lichen planus is sometimes associated with infections or auto immune diseases and / or neoplasia, but the association had not been established. A more consistent association was found between chronic liver disease and erosive form of OLP. Recent studies indicate an association between Hepatitis C Virus (HCV) and OLP [9-11].

Oral lichenoid reactions caused by drugs and dental restorative materials have been considered as variants of OLP. Drugs implicated are non – steroidal antiinflammatory agents, sulfonyl ureas, beta blockers, oral hypoglycemic agents, dapsone, pencillamine. Dental restorative materials like amalgam, composite, acrylic, gold have been reported to cause lichenoid reactions. Lichenoid lesions have also been reported in tobacco chewers; however, the causative role of tobacco in the pathogenesis of OLP has not been identified [5].

## Pathogenesis

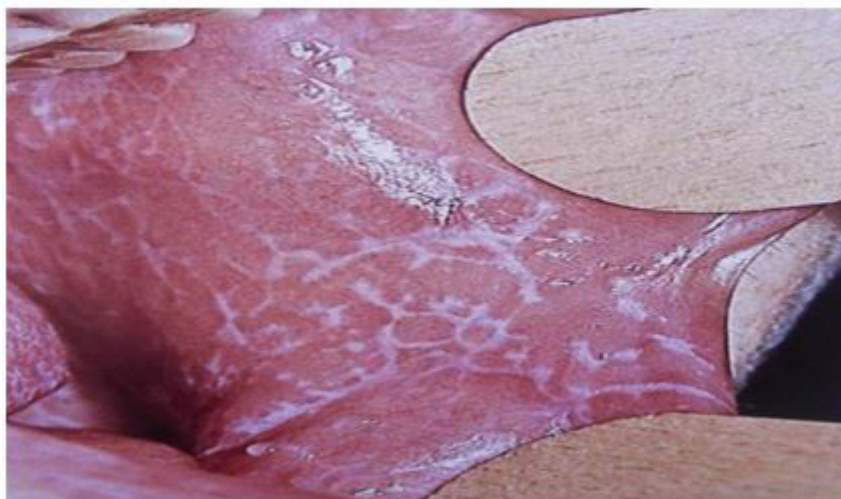OLP is caused by cluster of differentiation 8 (CD-8) cell mediated damage to the basal keratinocytes leading to apoptosis. The antigen inciting the cytotoxic T cells could be any of the above mentioned factors including stress, chronic liver disease, HCV virus, dental restorative materials and/or drugs [5]. The main event in the pathogenesis appears to be increased production of cytokines leading to the recruitment of Langerhans cells and clonal expansion of cytotoxic cells. Langerhans cells produce increased amounts of interferon-alpha (IFN -  $\alpha$ ), which further activates cytotoxic cell mediated apoptosis, via the keratinocyte caspase cascade [1,12]. Inter-cellular adhesion molecules enhance the attraction of cytotoxic T cells. Interferon - $\gamma$  production increases the apoptosis through the up regulation of p53 and matrix metallo proteinase-1 (MMP-1) [1]. Non-specific mechanisms like mast cell degranulation and MMP -1 activation further aggravate the T cell accumulation, basement membrane disruption by mast cell proteases and keratinocyte apoptosis (triggered by basement membrane disruption). The chronicity of the OLP lesions might be partly explained by the fact that the basement membrane disruption triggers keratinocyte apoptosis and apoptotic keratinocytes are unable to repair the breach in basement membrane [12].

## Clinical features of oral lichen planus

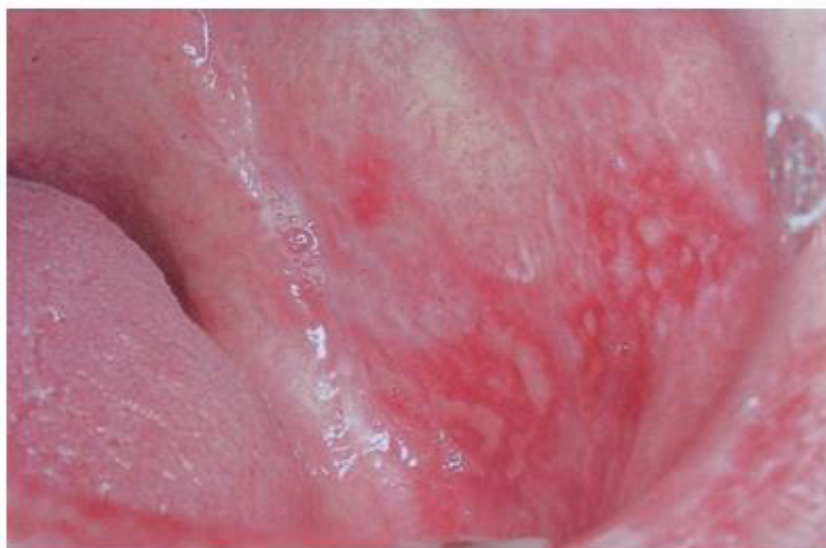The clinical picture of OLP varies from small barely visible fine white lesions to large areas that can affect the entire oral mucosa. The symptoms are variable, ranging from no symptoms to severe intraoral pain. About two-thirds of the patients describe a burning sensation and pain in the area of the oral mucosa, which leads to difficulties and restrictions in eating, speaking and swallowing. Natural courses of OLP usually involve active disease phases and periods of remission. Periods of exacerbation are generally associated with psychological stress and anxiety and during this time there is increased erythema or ulceration with increased pain and sensitivity. According to Andreasen's clinical classification, reticular, papular, plaque, atrophic, erosive-ulcerative and bullous forms can be distinguished [4]. The reticular form (Figure 1) is the most common type. It clinically presents as papules and plaques with interlac-

ing white keratotic lines (wickham's striae) surrounded by an erythematous border. Wickham's striae are usually bilateral and seen on buccal mucosa, mucobuccal fold, gingiva and rarely on palate, tongue and lips. This type is reportedly more common in males than females and it is usually asymptomatic [13]. Atrophic/erythematous and erosive/ulcerative (Figure 2) lesions are symptomatic. Symptoms include mucosal sensitivity, burning sensation and continuous debilitating pain. OLP involving the gingiva is termed as "desquamative gingivitis" (Figure 3) which clinically manifest as afiery red erythema of attached gingiva. Plaque-like.

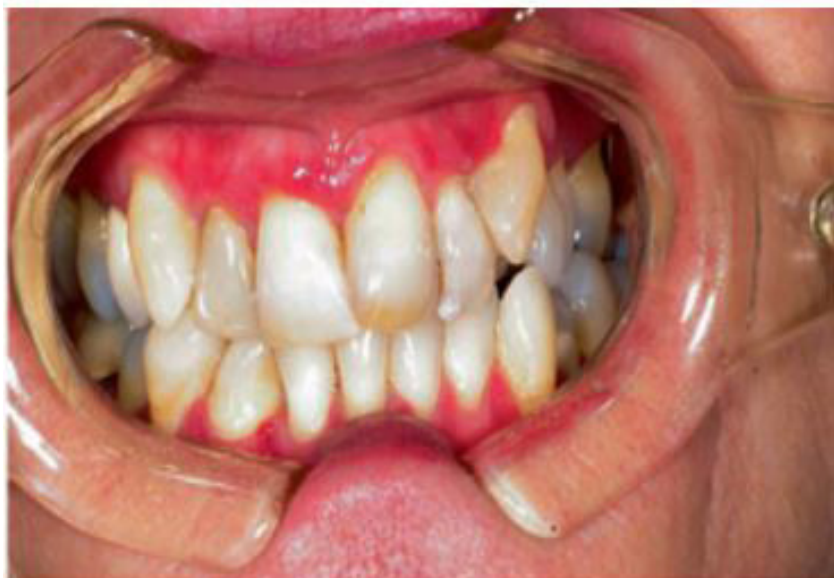This type shows whitish homogeneous irregularities similar to leukoplakia; it mainly involves the dorsum of the tongue and the mucosa of the cheek (Figure 4). OLP lesions which are associated with patchy brown melanin deposits in the oral mucosa are termed as inflammatory melanosis [12].



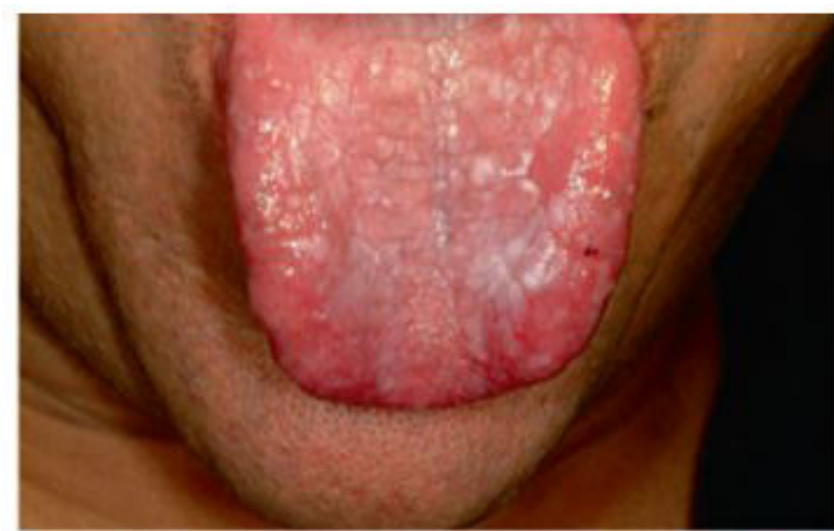**Figure 1:** Reticular form of oral lichen planus [4]



**Figure 2:** Erosive form of oral lichen planus [4]



**Figure 3:** Desquamative gingivitis OLP [4]



**Figure 4:** Atrophic and plaque-like OLP [4]

## Diagnosis

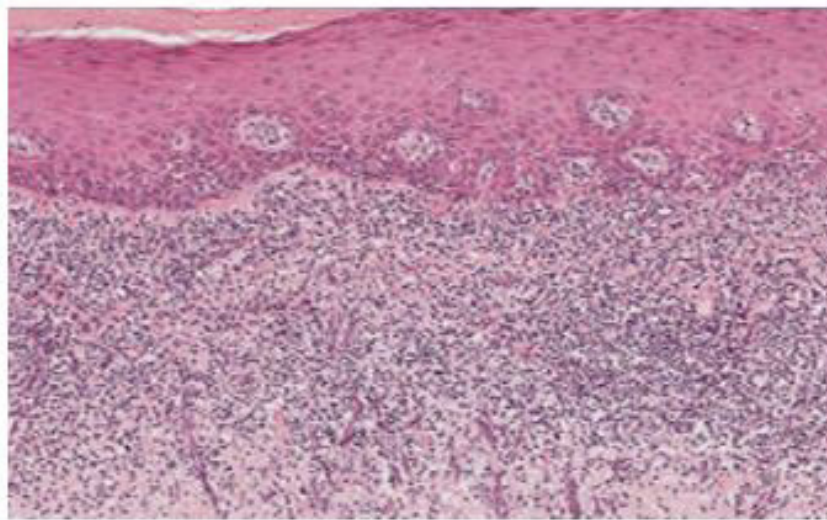
The characteristic clinical aspects of OLP (symmetry, bilateral distribution) are thought by some researchers to be sufficient to make a correct diagnosis especially if there are classic skin lesions present. However, an oral biopsy with histopathologic study is usually recommended to confirm the clinical diagnosis and mainly to exclude dysplasia and malignancy [5].

The classic histopathologic features of OLP include liquefactive degeneration of the basal cell accompanied by apoptosis of the keratinocytes, a dense band-like lymphocytic infiltrate at the interface between the epithelium and the connective tissue, focal areas of hyperkeratinized epithelium and occasional areas of atrophic epithelium where the rete pegs may be shortened and pointed (a characteristic known as saw tooth rete pegs). Eosinophilic colloid bodies (Civatte bodies), which represent degenerating keratinocytes, are often visible in the lower half of the surface epithelium (Figure 5a and b).

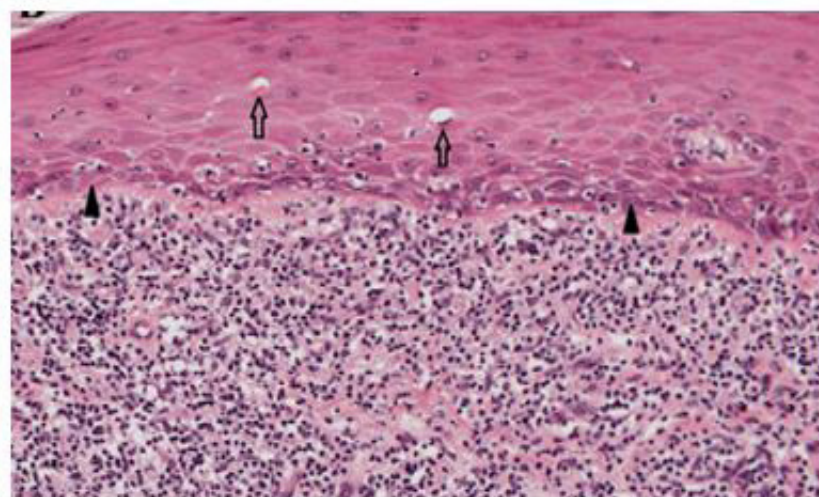
The histopathologic assessment of OLP has been described as a subjective and insufficiently reproducible process and in about 50% of OLP cases; there is a lack of clinicopathologic correlation in the diagnostic assessment of OLP [14]. Gingival LP may be more difficult to diagnose, and direct immunofluorescence of perilesional mucosa may facilitate the diagnosis and exclude other causes such as vesiculobullous diseases. The value of direct immunofluorescence for confirmation of the disease is well accepted, especially with nondiagnostic histopathologic features and for the desquamative gingivitis form of OLP [15].

Direct immunofluorescence studies of OLP have shown a linear pattern and intense positive fluorescence with antifibrogen outlining the basement membrane zone and cytooid-like bodies with positive immunoglobulin M labeling [12,15]. There are no consistent serological changes associated with OLP but some patients do present an elevated antinuclear antibody (ANA) titer. Although cytological changes may be detected in OLP, the use of exfoliative cytology is not recommended [12]. Some studies show an increased incidence of *C. albicans* infection in patients with OLP. Periodic acid-Schiff (PAS) staining of biopsy specimens and candidal cultures or smears may be performed.

The differential diagnosis can include cheek chewing/frictional keratosis, leukoplakia, lichenoid reactions, leukoplakia, lupus erythematosus, pemphigus, mucus membrane pemphigoid, para neoplastic pemphigus, erythematous candidiasis and chronic ulcerative stomatitis, Graft vs. host disease [16].



**Figure 5a:** Histopathology of OLP: showing parakeratosis, band-like subepithelial chronic inflammatory infiltrate, and saw tooth rete ridges (H&E,X100)



**Figure 5b:** High-power photomicrograph showing several colloid bodies and liquefactive degeneration of basal keratinocytes (H&E, X200)

## Malignant Potential of OLP

Malignant transformation of OLP remains a very controversial issue [17]. At least some reported cases diagnosed originally as OLP on clinical and/or histological grounds were probably epithelial dysplasia (lichenoid dysplasia) that progressed subsequently to overt squamous cell carcinoma (SCC). The OLP lesions are consistently more persistent than the dermal lesions and have been reported to carry a risk of malignant transformation to *oral squamous cell carcinoma* (OSCC) of 1-2% (reported range of malignant transformation 0-12.5%) [18]. *Erythroplastic* lesions may also occur in OLP.

They develop in approximately 1% of the patients and are sharp with slight reddish depressions. In most cases, malignant transformation to *carcinoma in situ* (28.5%) and in *micro invasive carcinoma* (30-38%) is observed, less frequently stage I and II carcinoma [19]. Oral cancer-correlated OLP predisposes to the development of multiple *primary metachronous tumors* of the oral cavity and of lymph node metastases. The metastatic capacity of carcinomas developing in OLP has been addressed by an earlier report by Mignogna et al. [20] who showed that 24% of these patients had detectable lymph node metastases at the time of diagnosis. In their more recent work, the same authors [16] reported that 94% of 97 neoplastic events observed were TisN0M0 or T1N0M0 (intraepithelial neoplasia or microinvasive carcinoma <1 mm) and 6% were stage III (three tumors) or IV (three tumors).

## Management of OLP

The principal aims of current OLP therapy are the resolution of painful symptoms, oral mucosal lesions, the reduction of the risk of oral cancer, and the maintenance of good oral hygiene. Eliminate the local exacerbating factors as preventive measures. Up to now different therapies are described for OLP including drug therapy, surgery, psoralen with ultraviolet light A (PUVA), and laser. Use of novel drug therapy is the most common method for treatment of OLP. Different drugs have been used in the form of topical and systemic application for the treatment of OLP [21]. Drugs used in topical form are corticosteroids, immunosuppressives, retinoids, and immunomodulators. Drugs which are used systemically are thalidomide, metronidazole, griseofulvin, and hydroxychloroquine, some retinoids and corticosteroids. Small and accessible erosive lesions located on the gingiva and palate can be treated by the use of an adherent paste in the form of a custom tray, which allows for accurate control over the contact time and ensures that the entire lesional surface is exposed to the drugs [22].

Surgical excision, cryotherapy, CO 2 laser, and ND:YAG laser have all been used in the treatment of OLP. In general, surgery is reserved to remove high-risk dysplastic areas.

Photo chemotherapy, a new method in which clinician uses ultraviolet A (UVA) with wavelengths ranging from the 320 to 400 nm, after the injection of psoralen is also used. Relaxation, meditation and hypnosis have positive impact on many cutaneous diseases and help to calm and rebalance the inflammatory response which can ameliorate inflammatory skin disorders [23]

## Follow-up

Patient follow-up ranging from every 2 months to annually is accepted as part of long-term care for patients with OLP largely to screen for changes that may indicate malignant transformation [16]. More frequent examinations are recommended for patients with OLL with dysplasia [5]. If changes are noted in a lesion at follow-up visits, then an additional biopsy or biopsies should be performed and the follow-up intervals shortene. For those OLP patients who develop OSSC, Mignogna et al. [20] proposed the strict followup of patients with oral and neck examinations every 2 months during the 5- to 9-month period after the diagnosis of oral carcinoma, when the risk of metastasis or second primary tumor is maximum.

## Conclusion

OLP is a very common oral dermatitis and is one of the most frequent mucosal pathoses encountered by dental practitioners. Interaction of various factors is probably responsible for the initiation, aggravation and persistence of OLP. The current treatment modalities are not only inadequate in treating all patients and preventing recurrences, but also have significant side effects. It is imperative that the lesion is identified precisely and proper treatment be administered at the earliest. A proper understanding of the pathogenesis, clinical presentation, diagnosis of the disease becomes important for providing the right treatment, thus significantly reducing the morbidity of OLP patients.

## References

1. Carazzo M, Thorpe R (2009) Oral lichen planus: a review. *Minerva Stomatol* 58: 519.
2. Femiano F, Scully C (2005) Functions of the cytokines in relation oral lichen planus-hepatitis C. *Med Oral Patol Oral Cir Bucal* 10: E40-4.
3. Strauss R, Fattore L, Soltani K (1989) The association of mucocutaneous lichen planus and chronic liver disease. *Oral Surg Oral Med Oral Pathol* 68: 406.
4. Andreasen J (1968) Oral lichen planus 1A clinical evaluation of 115 cases. *Oral Surg Oral Med Oral Pathol* 25: 31-42.
5. Ismail SB, Kumar SK, Zain RB (2007) Oral lichen planus and Lichenoid reactions; Etiopathogenesis, diagnosis, management and malignant transformation. *J Oral Sci* 49: 89-106.
6. Mc Cartan BE (1995) Psychological factors associated with oral lichen planus. *J Oral Pathol Med* 24: 273-5.
7. Scully C, Potts A, Hamburger J, Wiesenfeld D, McKee J, et al. (1985) Lichen planus and liver disease: how strong is the association. *J Oral Pathol* 14: 224-6.
8. Lozada- Nur F, Miranda C (1997) Oral lichen planus: epidemiology, clinical characteristics and associated diseases. *Semin Cutan Med Surg* 16: 273-7.
9. Lodi G, Giuliani M, Majorana A, Sardella A, Bez C, et al. (2004) Lichen planus and hepatitis C virus: A multicentre study of patients with oral lesions and a systematic review. *Br J Dermatol* 15: 1172-81.
10. Al Robaee A, Alzolibani A (2006) Oral lichen planus and hepatitis C virus: Is there real association? *Acta Dermatoven* 15: 15-9.
11. Bagon J, Aguirre J, del Olmo J, Milion A, Pearrocha M, et al. (1994) Oral lichen planus and chronic liver disease: A clinical and morphometric study of oral lesions in relation to transaminase elevation. *Oral Surg Oral Med Oral Pathol* 78: 337-42.
12. Sugerma P, Savage N, Walsh L, Zhao Z, Zhou X, et al. (2002) The pathogenesis of oral lichen planus. *Crit Rev Oral Biol Med* 13: 350-65.
13. Munde A, Karle R, Wankhede P, Shaikh S (2013) Demographic and clinical profile of oral lichen planus: A retrospective study. *Contemp Clin Dent* 4: 181-5.
14. van der Meij E, Mast H, van der Waal I (2007) The possible premalignant character of oral lichen planus and oral lichenoid lesions: a prospective five-year follow-up study of 192 patients. *Oral Oncol* 43: 742-8.
15. Eisen D, Carrozzo M, Bagan Sebastian JV, Thongprasom K (2005) Number V Oral lichen planus: clinical features and management. *Oral Dis* 11: 338-49.
16. Mignogna M, Fedele S, Lo Russo L, Mignogna C, de Rosa G, et al. (2007) Field cancerization in oral lichen planus. *Eur J Surg Oncol* 33: 383-9.
17. Shafer W, Hine M, Levy B (2009) Shafer's textbook of oral pathology (6<sup>th</sup> Edn) Elsevier publications: Noida, India.
18. Gonzalez-Moles M, Scully C, Gil-Montoya J (2008) Oral lichen planus: Controversies surrounding malignant transformation. *Oral Dis* 14: 229-43.



19. Canto A, Müller H, Freitas R, Santos P (2010) Oral lichen planus (OLP): Clinical and complementary diagnosis. *An Bras Dermatol* 85: 669-75.
20. Mignogna M, Lo Muzio L, Lo Rosso L, Fedele S, Ruoppo E, et al. (2001) Clinical guidelines in early detection of oral squamous cell carcinoma arising in oral lichen planus: A 5- year experience. *Oral Oncol* 37: 262-7.
21. Sahebamee M, Arbabi-Kalati F (2005) Management of oral lichen planus. *Arch Iranian Med* 8 :252-6.
22. Lavanya N, Jayanthi P, Rao U, Ranganathan K (2011) Oral lichen planus: An update on pathogenesis and treatment. *J Oral Maxillofac Pathol* 15: 127-32.
23. Aghahosseini F (2006) Treatment of oral lichen planus with photodynamic therapy mediated methylene blue: A case report. *Med Oral Pathol Oral Cir Bucal* 11: 126-9.